

# Three-Dimensional Analysis of Scoliosis Surgery Using Stereophotogrammetry

Stanley B. Jang\* and Kellogg S. Booth

Department of Computer Science, University of British Columbia  
Vancouver, British Columbia, Canada

Chris W. Reilly, Bonita J. Sawatzky and Stephen J. Tredwell

Department of Orthopaedics, B.C. Children's Hospital  
Vancouver, British Columbia, Canada

## ABSTRACT

Scoliosis is a deformity characterized by coronal, sagittal and axial rotation of the spine. Surgical instrumentation (metal pins and rods) and eventual fusion are required in severe cases. Assessment of the correction requires enough accuracy to allow rational proactive planning of individual interventions or implant design. Conventional 2-D radiography and newer 3-D CT scanning do not provide this accuracy.

A new stereophotogrammetric analysis and 3-D visualization allow accurate assessment of the scoliotic spine during instrumentation. Stereophoto pairs taken at each stage of the operation and robust statistical techniques are used to compute 3-D transformations of the vertebrae between stages. These determine rotation, translation, goodness of fit, and overall spinal contour. A polygonal model of the spine using a commercial 3-D modeling package is used to produce an animation sequence of the transformation.

The visualizations have provided some important observations. Correction of the scoliosis is achieved largely through vertebral translation and coronal plane rotation, contrary to claims that large axial rotations are required. The animations provide valuable qualitative information for surgeons assessing the results of scoliotic correction. A detailed study of de-rotation provided by different instrumentation systems and the assessment of hook position patterns is underway.

## 1 INTRODUCTION

Scoliosis is a three-dimensional deformity of the spine, characterized by rotations in all three planes of view. In the posterior view, the spine is an "S" curve as opposed to a vertical column in a normal spine. In the lateral view, a normal spine would be an "S" curve whereas the scoliotic spine is fairly straight. In the axial view (from the head looking down), some of the vertebrae are twisted about the spinal axis. Scoliosis is a common problem among children and adults. There are a variety of different types of scoliosis. The curve may

develop, secondary to a neuromuscular disorder, such as spina bifida or cerebral palsy. It may be congenital, due to an underlying abnormality of the formation of the spine. In many cases no cause of the scoliosis can be determined, commonly termed idiopathic scoliosis. Progression or worsening of the scoliotic curve can result in serious compromises in pulmonary and cardiac function. In the idiopathic group, non-operative treatment using braces is often successful. However, approximately 20% of the patients with scoliosis requiring treatment will undergo surgical intervention. Spinal fusion stops the progression of a curve that may lead to debilitating back problems, compromised pulmonary and cardiac function, and a gross cosmetic deformity in adulthood. Surgical spinal instrumentation systems, required to achieve predictable fusion of the spine, are used to correct the scoliosis towards a more normal spinal contour.

The cosmetic deformity is the actual adaptation of the rib cage, so that on the convex side of the curve a prominent rib hump often develops. This deformity can be measured clinically using a special level device placed on the back when the patient flexes forward, called a scoliometer. This measurement describes the clinical rib hump deformity. The rib hump is said to be due to the vertebral body rotation (twisting).

In the past 25 years the surgical management of spinal deformities has undergone tremendous changes. Modern spinal instrumentation systems have provided lasting correction of the sagittal (lateral) and coronal (posterior) plane spinal deformity present in idiopathic scoliosis. The surgical procedure involves securing hooks onto strategic vertebrae, correcting the shape and orientation of the spine, stabilizing that position by clamping stainless steel rods to the hooks, and finally, fusing the spine. Fusion is accomplished by placing bone graft and bone marrow obtained by the patient's hip, between the vertebrae.

Recently developed systems, such as Cotrel-Dubousset instrumentation (CDI), have attempted to address all of the components of the scoliotic deformity, including the axial rotational deformity. This is of importance because it is believed that the rib hump deformity described earlier is caused by the twisting in the vertebrae. However, accurate measurement of three-dimensional changes produced by spinal instrumentation has yet to be achieved and debate continues regarding axial rotation changes. It remains unclear whether current instrumentation techniques do establish true vertebral de-rotation or if they are merely due to pure translation of the vertebral column. There have been a number of approaches to accurately compute the rotational and translational changes in the vertebrae.

## 2 PREVIOUS ANALYSIS TECHNIQUES

Many techniques have been applied in attempts to define the three dimensional spinal anatomy in idiopathic scoliosis. Some of these techniques have been applied pre- and post- operatively in an attempt to quantify the effect of spinal instrumentation. A method of rotational assessment using plain AP radiographs with a torsionmeter was developed by Nash and Moe. This system has been assessed and found to be unacceptable for the clinical assessment of vertebral rotation<sup>3,15</sup>. Drerup modified the plain radiographic technique by using standard vertebral parameters to relate pedicle position and rotation to the estimated center of the vertebral body<sup>6</sup>. This improved the accuracy of the plain radiographic technique with a reported standard deviation of five degrees. Drerup's technique and three similar methods have been compared using an isolated single vertebrae rotated by fixed amounts in a bench study. Mean error was of a similar magnitude averaging four degrees<sup>14</sup>. The technique has not been used successfully to define rotational correction in post-operative patients.

CT scanning has been widely used in an attempt to compare pre- and post-operative vertebral position. The technique uses single slices through the spinal segment being assessed. A difficulty with the technique has been a lack of a standard reference frame to control for changes in gantry positioning pre- and post-operatively. Vertebral rotation has also been assessed segmentally utilizing CT cuts along the entire spinal axis and measuring post-operative segmental de-rotation<sup>17</sup>. Studies using both techniques have produced results with marginal accuracy. Lack of a standard reference frame between pre- and post-operative studies compounds this problem. CT scanning

techniques are also limited due to the radiation exposure, which prevents routine three dimensional reconstructions of scoliotic patients. The presence of metal instrumentation also causes significant image artifacts in both single slice and three dimensional reconstructions.

Many investigators have utilized stereoradiographic techniques to accurately measure the three dimensional anatomy of the scoliotic spine <sup>2,4,5,7,9,11,12,16</sup>. These systems commonly use conventional AP and a 20 degree caudal tilted view or a 50 degree oblique projection. They rely on stereodigitization of radiographic features of the vertebrae to produce 3-D coordinates. The technique is limited due to the inherent inaccuracy produced in selecting radiographic landmarks leading to reconstruction errors of up to 5mm for translation values <sup>1</sup>. In post-operative patients, landmark identification is more difficult due to the presence of the instrumentation and bone graft. This degree of error limits the ability of the technique to quantify the amount of de-rotation expected.

The presence of spinal instrumentation, the complex three-dimensional scoliotic deformity and the changes in vertebral anatomy seen in scoliosis have made accurate measurement difficult. Current techniques do not conclusively define vertebral de-rotation that is theoretically produced with systems such as CD instrumentation. Also, intra-operative changes created during the distraction and rotation phases of CD instrumentation have not been assessed by any investigators.

### **3 STEREPHOTOGRAMMETRIC ANALYSIS OF SCOLIOSIS**

A system of stereophotogrammetric analysis and 3-D visualization has been developed to allow accurate 3-D assessment of the scoliotic spine during spinal instrumentation. Stereophoto pairs are taken at sequential phases of the operative procedure. Multiple data points digitized from the stereo photos allow the calculation of 3-D positions for the vertebrae at each stage of the procedure with statistical techniques employed to provide a measure of the robustness of the results.

#### **3.1 Stereo Digitization**

Data for the analysis of the scoliosis surgery are acquired from stereo pairs of 35mm slides taken at six different stages of the operation. The slides are taken to a commercial company specializing in the stereo digitization of photos for the production of terrain maps. The slides are digitized using a two step process. Common landmarks distinguishable in each of the right-eye slides are marked directly on the slides with 50 micron burn holes. There are fewer landmarks to choose from in the photos of the later stages because of the instrumentation already in place, and because parts of some of the vertebrae are chipped off. Typically, landmarks found in the last stage of the operation, when all of the surgical implants are in place, are visible in all the previous stages. With the landmarks to be used clearly marked in the right-eye slides, stereodigitizing these points is relatively simple. As many as ten points are digitized for each fully exposed vertebra, although only three points are necessary to mathematically determine the position and orientation of a single vertebrae. Digitizing redundant points allows for increased accuracy in the calculations.

#### **3.2 Analysis of 3-D Data and Computation of Results**

The data from the slides consist of the "camera" coordinates of landmark points on each vertebrae at each stage of the operation. Before computing translations and rotations of the vertebrae from this data, the coordinates need to be converted to a "patient" coordinate system. This is accomplished with the aid of a metal ruler taped to the patient's skin just above the pelvis. This ruler is considered fixed relative to the spine. The data from

each of the stages is converted so that the ruler is aligned in each of the slides, putting all of the data points in the same coordinate system.

The change in position of each vertebra between any two stages can be computed from the data. The most interesting result for analyzing the success of the operation is the transformation between the first stage of the operation (initial surgical exposure of spine) and the last stage (the end of surgery just prior to closing the incision). Transformations between intermediate stages are relevant for studying the concepts behind the surgical procedure. Translations for each vertebra are computed from the center of mass of the vertebra's data points and are stated as X, Y, and Z values. Vertebral rotations are computed by finding the rotation matrix that best matches the corresponding data points for the vertebra between the two stages. This is a familiar problem in linear algebra known as the "orthogonal Procrustes problem" <sup>10</sup>. This problem explores the possibility that one subspace may be rotated into another. It is stated precisely as follows:

minimize  $|A - BQ|$  subject to the constraint that  $Q^tQ = I$  where  $A$  and  $B$  are the  $n \times 3$  data matrices specifying the two stages of vertebral data and  $Q$  is an unknown  $3 \times 3$  rotation matrix.

The solution calculates the rotation matrix  $Q$  that satisfies the equation and the constraints using the Frobenius norm as the error metric <sup>13</sup>. If less than three pairs of points are used, the problem is under-determined. If exactly three pairs of points are used and there is no error in the data, a single closed form solution exists. But if more than three pairs are used, the problem is over-determined. The minimization described achieves a "best solution" subject to an error metric. The algorithm to compute  $Q$  is as follows:

Let  $C = B^tA$   
Compute the singular value decomposition (SVD)  $U^tCV$   
Then  $Q = UV^t$

Rotation results are stated as a rotation amount about a unique axis and also as projections onto the three orthogonal planes in the posterior, lateral and axial views. This later representation is used strictly for ease of visualization and comparison.

### 3.3 Statistical Analysis of Results

The statistical analysis of the results is performed using a resampling technique known as "bootstrapping" <sup>8</sup>. This technique involves estimating the standard deviation,  $\sigma$ , of the raw data obtained from the stereo digitization and then running the data analysis program many times using perturbed data. An estimate of  $\sigma$  is calculated from the Frobenius norm of the matrix of rotation errors in the vertebra's data points and from the number of data points representing the vertebra. Using  $\sigma$ , the data is perturbed by a Gaussian displacement to simulate possible errors in the data. Rotation results are calculated from the perturbed data. This procedure is repeated many times, producing a large sample of rotation results. Standard deviations and other statistical values are calculated to provide an estimate of the accuracy achieved.

The bootstrapping technique is simple, yet accurate, assuming only that the sample standard deviation for the original data is accurate and that a sufficient number of samples are taken. The standard deviations for the translation results are computed directly from  $\sigma$ .

## 4 3-D VISUALIZATION OF SCOLIOTIC SPINE

The complexity of the scoliotic spine requires that 3-D graphical tools be developed to study the changes that occur during spinal instrumentation. A program was written to allow viewing of the data from different perspectives and to verify the accuracy of the rotations. Using a commercial 3-D modeller, an animation of the surgical correction of a patient's spine was created for subsequent visualization. This was accomplished by importing the digitized data into the modeller along with a "standard" polygonal model of a human spine obtained commercially. The model spine was scaled to fit the data and each vertebra was translated and rotated to match the pre-operative position of that of the patient's corresponding vertebra. Animation channels were generated from the translation and rotation results of the data and applied to the modified model vertebrae. The model spine could then be animated with lighting and shading to illustrate the initial position and the surgical correction of the patient's spine. This aspect of the project, although providing qualitative rather than quantitative results, has benefited the surgeons in assessing the results of the surgery. Not only are they able to watch the simulated surgical correction dynamically, but also are able to see it from different points of view, or from dynamic points of view. The commercial model does not detract since the curvature of the spine is what is wanted - the shape of the vertebrae is not as important.

## 5 PRELIMINARY RESULTS

This system of analysis has been carried out for four patients with idiopathic scoliosis who had undergone surgical correction using the Cotrel-Dubousset (CD) spinal instrumentation. Data were obtained for all fully exposed vertebrae during the operation. Rotation values for most of the vertebrae had a standard deviation of less than two degrees as determined by the bootstrapping statistical technique. Standard deviations for translation results were less than one millimeter. This accuracy surpasses that of previously reported techniques. Reviewing the results of these four cases has generated some important observations. Correction of the scoliosis is achieved largely through vertebral translation and coronal plane rotation, contrary to claims in the literature that large axial rotations are required. Despite excellent general curve correction, little or no axial de-rotation has been observed in the four cases studied so far. In addition to the quantitative measurements, the 3-D animations have provided valuable qualitative information for surgeons assessing the results of operative scoliotic correction.

## 6 FUTURE WORK

A program is currently being developed to perform stereo digitization of landmark points on the exposed vertebrae in a pair of digital stereo images. The matching of points in the stereo pair is accomplished using correlation matching, a standard technique in computer vision research. If successful, the data processing will no longer need to be performed by a third party allowing a more efficient analysis of the data. Improved accuracy is likely if images of high enough resolution are used. The digital images will be obtained from Kodak PhotoCD's. In addition to being economical and readily available, they are an excellent media for patient data archives.

A detailed study of the surgical correction, in particular of the axial de-rotation, for typical idiopathic adolescent patients using Cotrel-Dubousset instrumentation is currently underway. A study to compare the correction provided by different implant designs will follow. The long term goal is a better understanding of the true kinematics of the human spine. Proposals for alterations in surgical technique or in instrumentation can then be initiated. This information will aid orthopedic surgeons in improving scoliosis surgery and will influence future instrumentation system design.

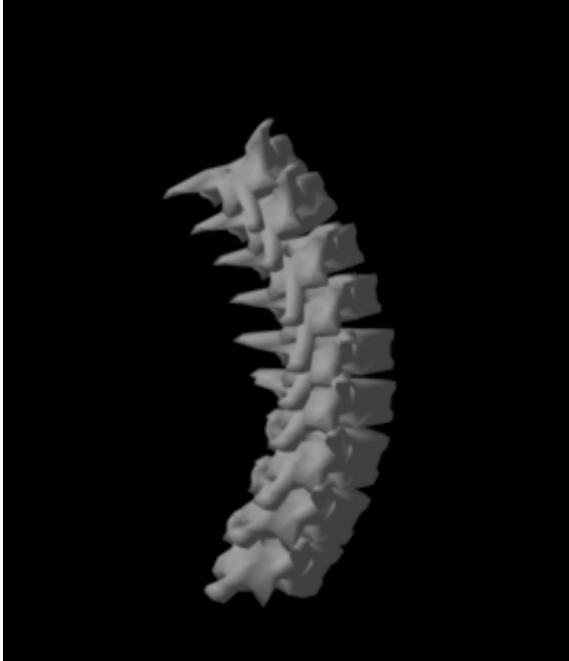
## 7 ACKNOWLEDGEMENTS

Financial support for this research was provided by the British Columbia Medical Services Foundation, the British Columbia Children's Hospital Telethon Funds, and the Natural Sciences and Engineering Research Council of Canada, and the Province of British Columbia.

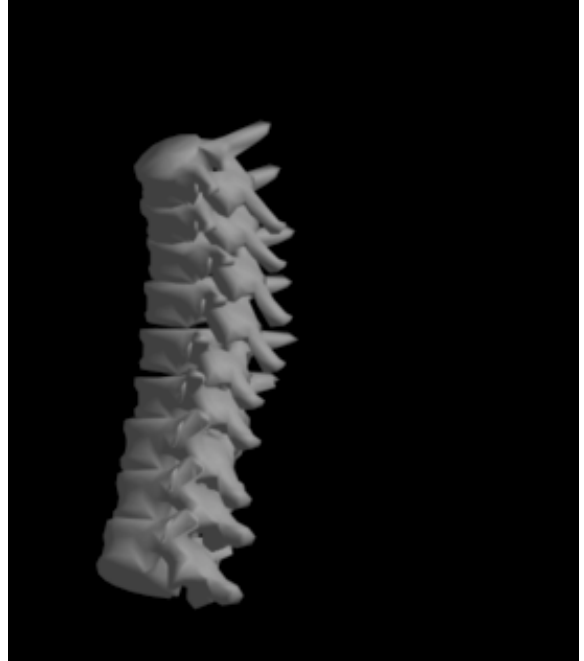
## 8 REFERENCES

1. Andre, B., et al, "Effects of Radiographic Landmark Identification Errors on the Accuracy of Three Dimensional Reconstruction of the Human Spine", *Medical and Biological Engineering and Computing*, pp. 569-575, Nov 1992.
2. Beauchamp, A., Dansereau, J., de Guise, J., Labelle, H., "Computer assisted digitization system for scoliotic spinal stereo radiographs", *International symposium on 3-D scoliotic deformities*, Montreal, Canada, June 1991.
3. Benson, D.R., Shultz, A.B., Dewald, R.I., "Roentgenographic evaluation of vertebral rotation" *JBJS 58-A*, p. 1125, 1976.
4. Brown, R. H., et al, "Spinal Analysis Using A Three Dimensional Radiographic Technique", *Journal of Biomechanics*, 9, pp. 355-365, 1976.
5. Dansereau, J., Beauchamp, A., de Guise, J., Labelle, H., "Three dimensional reconstruction of the spine and rib cage from stereoradiographic image techniques", *Societe Canadienne de G.M.*, Vol. 2, p. 61, 1990.
6. De Smet A.A., et al, "A Radiographic Method for Three- Dimensional Analysis of Spinal Configuration", *Diagnostic Radiology*, 137, pp. 343-347, 1980.
7. Drerup, B., "Improvements in measuring vertebral rotation from projection of the pedicles", *Journal of Biomechanics*, 18, p. 369, 1985.
8. Efron, Bradley, The Jackknife, the Bootstrap, and Other Resampling Plans, Philadelphia: Society of Industrial and Applied Mathematics, 1982.
9. Golub, G.H., Van Loan, C.H., Matrix Computations, Baltimore: John Hopkins University Press, 1983.
10. de Guise, J., Sabourin, R., Lalonde, J., "Development of a stereoradiographic correspondence method for the 3-D reconstruction of the scoliotic spine and rib cage", *International symposium on 3-D scoliotic deformities*, Montreal, Canada, June 1992.
11. Hindmarsh, J. et al, "Analysis of Changes in the Scoliotic Spine Using a Three Dimensional Radiographic Technique", *Journal of Biomechanics*, 13, pp. 279-290, 1980.
12. Kratky, V., "Analytical X-Ray Photogrammetry in Scoliosis", *Photogrammetria*, 31, pp. 195-210, 1975.
13. Leon, Steven J., Linear Algebra with Applications, 2nd Ed., New York: MacMillan Publishing Company, 1986.
14. Russell, G.G., et al, "A Comparison of Four Computerized Methods for measuring Vertebral rotation", *Spine* 15 (1) 1990.
15. Stephens, Richard B., "Measurement Error in Assessment of Vertebral Rotation Using the Perdriolle Torsionmeter", *Spine*, 17,(5),1992.
16. Stokes, I.A.F., "Three-Dimensional Spinal Curvature in Idiopathic Scoliosis", *Journal of Orthopaedic Research*, 5, pp. 102-113, 1987.

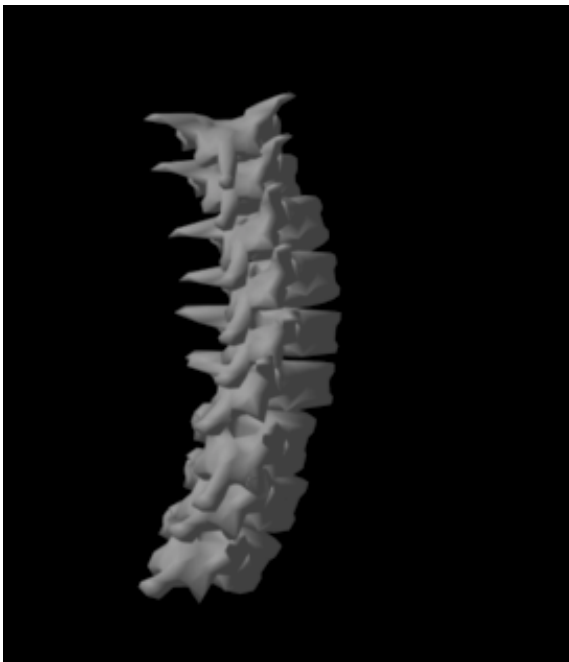
17. Transfeld, E., et al, "Three Dimensional Changes in the Spine Following Cotrel-Dubousset Instrumentation for Adolescent Idiopathic Scoliosis", *6th Cotrel-Dubousset Instrumentation*, pp. 73-79, 1989.



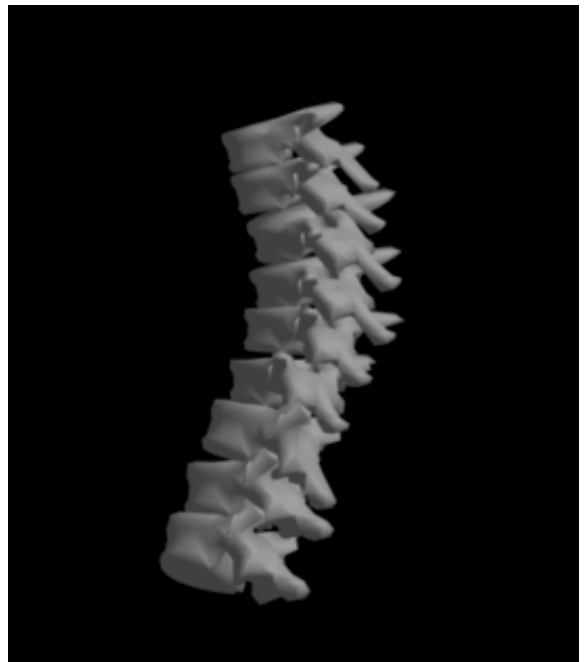Pre-operative scoliotic spine - posterior view



Pre-operative scoliotic spine - lateral view



Post-operative scoliotic spine - posterior view



Post-operative scoliotic spine - lateral view

Figure 1: The spine in these figures is a purchased polygonal model. The data for the initial orientation (pre-operative) and the animation that produced the final orientation (post-operative) is that of a real patient with idiopathic scoliosis who underwent surgical correction using Cotrel-Dubousset instrumentation. Notice the severe curvature in the posterior view of the pre-operative spine and the lack of curvature in the lateral view. In the post-operative spine, the curvature in the posterior view is decreased and the there exists some curvature in the lateral view.